Are Melanocytic Nevi Influenced by Pregnancy? A Dermoscopic Evaluation

MARIA ROSARIA ZAMPINO, MD,* MONICA CORAZZA, MD,* DEMETRIO COSTANTINO, MD,† GIOACCHINO MOLLICA, MD,‡ AND ANNAROSA VIRGILI, MD*

BACKGROUND Dermoscopic data of melanocytic nevi (MN) in pregnancy are very limited and related to small groups of women.

OBJECTIVE This study systematically analyzes dermoscopic parameters in a wide series of MN during and after pregnancy.

METHODS Eighty-six MN on the back of 47 women were studied. Dermoscopic parameters, total dermoscopic score (TDS) according to Stolz's ABCD rule, and the sizes of the nevi were evaluated over time.

RESULTS Progressive lightening of the nevi resulted at the end of pregnancy ($p<.05$) and after delivery ($p<.001$). Pigment network showed a progressive reduction in prominence and thickness (end of pregnancy, $p<.05$; after delivery, $p<.01$). At the end of pregnancy, vessels increased ($p<.05$) and a higher TDS was observed, with a significant reduction in both after delivery (vessels, $p<.05$; TDS, $p<.01$). Area changes were not statistically significant.

CONCLUSIONS At the end of pregnancy, both vascular structures and TDS increased. These modifications were transient as the nevi recovered their prior appearance after delivery. The results indicate that an intrinsic influence of pregnancy may induce structural modifications without influencing the size of the nevi. Behavioral factors during the observational period, like a reduced exposure to sunlight reported by most of the women, may have influenced other characteristics, like global pigmentation and pigment network.

The authors thank the Fondazione Cassa di Risparmio di Ferrara for its financial support, which enabled them to acquire the instrumentation necessary for this study.

Data regarding the influence of pregnancy on melanocytic nevi (MN) are still controversial. Changes like the enlarging or darkening of pigmented skin lesions have been commonly reported, generally on the basis of subjective observations.[1–4] Only few studies, however, have investigated objectively the actual changes of MN during pregnancy. A photographic follow-up of clinically benign MN in pregnant women did not demonstrate significant changes in size.[5] Furthermore, in other studies, histopathologic analysis of pigmented skin lesions from pregnant women has not confirmed a significant difference with the nonpregnant control group,[3,4] although a tendency toward a higher degree of atypia was observed in the study group.[4] A prospective photographic study performed in pregnant women with displastic nevus syndrome showed that clinical nevus changes and histologic displastic features were, respectively, 3.9 and 2 times more frequent in women who were pregnant than when they were not.[6]

Department of Clinical and Experimental Medicine, Section of Dermatology, and ‡Department of Biomedical Science and Advanced Therapy, Section of Obstetrics and Gynecology, University of Ferrara, Ferrara; †Azienda Unità Sanitaria Locale, Centro Salute Donna, Ferrara, Italy

ISSN: 1076-0512 • Dermatol Surg 2006;32:1497–1504 • DOI: 10.1111/j.1524-4725.2006.32362.x

Only few observations have been reported about dermoscopic changes of MN during pregnancy and, in some cases, after delivery.[7,8] The aim of the present study was to systematically evaluate dermoscopic findings of MN during pregnancy and postpartum in a group of white women.

Materials and Methods

From June 2001 to July 2002, a total of 60 pregnant white women were recruited by the Department of Obstetrics and Gynecology and sent to our Department of Dermatology for enrollment in the present study. Informed consent was obtained at the beginning of the observational period. The study protocol conformed to the guidelines of the 1975 Declaration of Helsinki and was approved by our institutional review board. The data were collected longitudinally through October 2003. The first visit (V1) was performed in the first trimester of pregnancy, between the 6th and the 12th weeks of gestation. Information regarding sun exposure habit, history of sunburns, personal response to sun exposure in terms of the degree of tanning, family history of displastic nevi, or melanoma was collected. All the women had not been sun exposed during the 4 weeks preceding the baseline consultation. Physical examination was performed to establish phenotypic characteristics like eyes, hair, and skin color, the latter referred to the upper inner arm. Phototype was also defined, according to Fitzpatrick's classification. Acquired clinically typical MN, defined as brown pigmented macules or papules sized more than 2 mm, were selected on the back, which represents an area poorly modified by morphologic changes related to pregnancy. Three women were excluded from the study because they had no nevi on their back. In the remaining 57 women, the location of each lesion was indicated on a body standardized diagram, where the back was divided into three areas corresponding to the scapular (A1), lumbar (A2), and sacrogluteal regions (A3), respectively. This subdivision was performed hypothesizing some variation related to the different anatomic areas. When the nevi on the back were more than one, the most representative ones—maximum three nevi—were chosen. Finally, examination by means of a digital surface microscopy video instrument using a 50 × magnification lens (Videocap 200, DS Medica, Milan, Italy) was performed, and the images were stored on a computer hard disk. Digital system was calibrated to operate in standardized condition at every visit.

Dermoscopic follow-up of each lesion was repeated at the third trimester of pregnancy (V2) and approximately 6 months after delivery (V3). To avoid the influence of sun exposure, all the women were asked to avoid exposure to sunlight in the 4 weeks preceding further dermoscopic examination. Digitized images were retrieved and examined side by side by three trained observers (MC, AV, and MRZ). After definition of the global pattern, the criteria indicated in Table 1 and/or their specific aspects, already described by other authors,[9–11] were evaluated and scored according to a scale ranging from 0 to 10 (0 = absent; 10 = prominent). The value of "sharpness" varied from 0 to 10 depending on the lesion, i.e., sharp or faded. Each of the dermoscopic images was also assessed with the ABCD rule,[12] and the total dermoscopic scores (TDS) were recorded. The area of each lesion was measured by a computer-assisted measurement system (Videocap software, Milan, Italy).

The scores and the measures obtained were then submitted to statistical processing mainly by means of an ANOVA-RM procedure and, when needed, by analogous nonparametric ones (Kruskal–Wallis, Friedman) employing SPSS Version 8 statistical package (SPSS Inc., Chicago, IL). Changes were considered significant when p values were less than .05. From a practical point of view, we considered the dermoscopic parameters modified when at least two of three observers registered a significant change.

Results

Among 57 women eligible for the study, 8 did not conclude all visits,

TABLE 1. Dermoscopic Criteria Evaluated by Each Observer

Criterion	*Specific aspects**
Global intensity of brown pigmentation	—
Symmetry related to	Shape
	Color
	Dermoscopic structures
Pigmented network (network of brownish lines over a diffuse tan background)	Intensity of pigmentation
	Regularity of mesh
	Width of mesh
	Broadness of lines
	Sharpness of border†
Dots/globules (black, brown or gray rounded to oval areas sharply demarcated)	Prominence
	Number
	Size
	Regularity of shape
	Regularity of distribution
Blotches (black, brown or gray pigmented areas)	Intensity of pigmentation
	Size
Streaks (linear structures not clearly combined at the margins with pigment network lines)	Number
Hypopigmented areas (light brown areas without network or lines)	Size
Vascular structures	Number
Comma-like	
Arborizing	
Hairpin	
Dotted	
Irregular	

*0–10 = absence-prominence of the parameter
†0–10 = sharp-faded

because 2 of them had a spontaneous abortion at the 11th week of pregnancy, whereas an additional 6 abandoned the study before it ended and did not come to V2 or V3. Therefore, 49 were completely followed up until the postpartum period (V3). The images of 2 of the 49 women, however, were excluded for technical reasons (poor quality or incomplete inclusion of the lesion in the monitor area). Therefore, in the remaining 47 women (range, 26–40 years; mean ± SD, 32.3 ± 3.5), a total of 86 dermoscopic images obtained from the back had dimensional (complete inclusion within the screen) and quality characteristics suitable for dermoscopic and statistical evaluation over time. The number of the nevi monitored for each woman ranged from 1 to 3. Thirty-four women were at their first pregnancy, 12 at the second, and 1 at the third. Nineteen women had been classified as skin phototype II, 26 as type III, and 2 as type IV. The total number of nevi on the body ranged from 2 to 82 (mean ± SD, 18.1 ± 15.5). Three women had a family history of melanoma, and 1 of displastic nevus syndrome. The latter had the highest number of nevi (82) on the body. At dermoscopic examination, the global pattern was reticular in 59 nevi, globular in 15, and homogeneous in the remaining 12.

Behavior of Dermoscopic Parameters

General Observations Statistical processing showed that almost always the three observers reported the same results with only slight statistical differences. No significant changes resulted comparing the different areas (A1, A2, A3) of the back. Dermoscopic changes were generally mild, and surgical excision was never considered necessary.

Global Pigmentation A progressive clearing of the brown color was observed at the end of pregnancy (V1 vs. V2, $p<.05$) and, particularly, 6 months after delivery (V2 vs. V3, $p<.001$).

Symmetry Symmetry, related both to the color and to the dermoscopic structures, was more evident in the postpartum period (V3) compared with V1 ($p<.01$) and V2 ($p<.01$).

Pigmented Network A pigmented network was observed as local pattern in a series of 78 pigmented lesions examined in 44 women. Prominence and thickness of lines showed a progressive reduction in time (V1 vs. V2 $p<.05$; V1 vs. V3 $p<.01$). Width of meshes increased at the end of pregnancy ($p<.05$) but did not vary significantly at the successive postpartum visit. The borders were

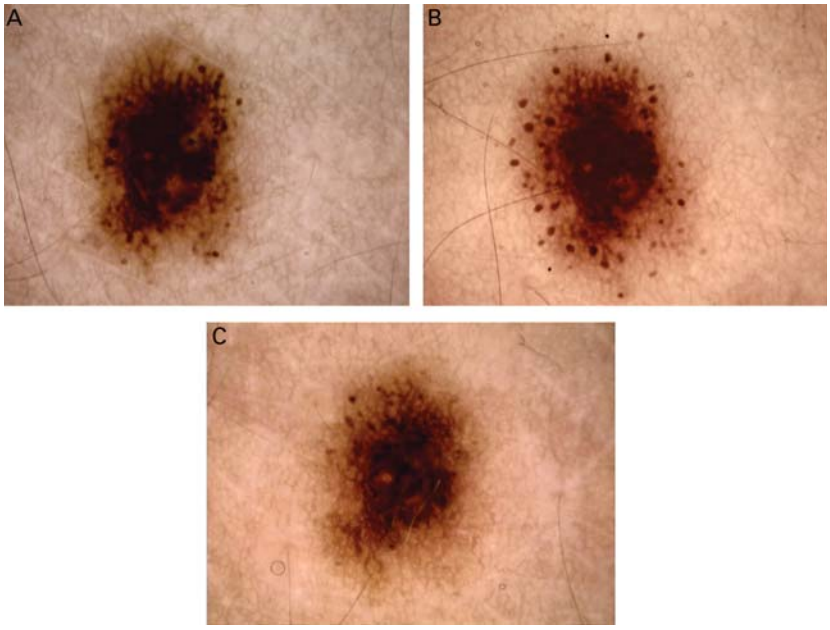

Figure 1. (A) Dermoscopic feature of a melanocytic nevus on the scapular area at the ninth week of pregnancy. Area, 7.5 mm^2. (B) Development of new globules regularly distributed around the periphery at the end of pregnancy. Area, 8.2 mm^2. (C) Disappearance of peripheral globules six months after delivery. Area, 7.6 mm^2.

more faded at V3 when compared with V1 ($p<.05$) and V2 ($p<.05$).

Dot/globules Dot/globules were always present as local pattern in 57 nevi observed in 39 women. A significant reduction in the number ($p<.02$) and size ($p<.04$) of dot/globules was observed at the postpartum visit when compared with the end of pregnancy.

Comparing the last visit with the first one, all observers agreed on the clearing of the pigmentation of the globules. Their evaluation, however, remained just under the statistical significance threshold.

Regularity of size and distribution of dot/globules was not affected by the anatomic area, nor by the time of observation. In detail, at the end of pregnancy (V2) a reversible rim of peripheral globules (Figure 1) developed in two nevi of two women: the size resulted reversibly increased for the nevus located in the scapular area (V1, 7.5 mm^2; V2, 8.2 mm^2; V3, 7.6 mm^2), while the nevus located in the lumbar area showed a progressive little enlargement (V1, 7.4 mm^2; V2, 8.2 mm^2; V3, 8.5 mm^2).

Apart from the nevi in which globules were always detected as local pattern, for other 10 nevi of nine women, a variable presence of globules over time was observed: in 4 of these nevi, globules with a prevailing peripheral distribution were present at the beginning and at the end of pregnancy and disappeared completely at the postpartum visit. In 2 other cases, a few globules appeared in the context of the peripheral area of the nevus only at the end of the pregnancy and disappeared completely at the postpartum visit. In the remainder of the nevi, globules with prevailing central, peripheral, or homogeneous distribution were always present except at the beginning (2 cases) or at the end of pregnancy (2 cases).

Blotches Blotches were present in 18 nevi belonging to 14 women. A significant reduction in their size ($p<.01$) and darkness ($p<.01$) was observed at the postpartum visit when compared with the end of pregnancy. Size also showed values significantly smaller comparing the postpartum period with the beginning of the pregnancy (V1 vs. V3, $p<.04$). In the same interval of time, darkness showed a similar trend near to but not reaching the significance threshold.

Hypopigmented Areas Localized areas were present in 11 nevi and multifocal hypopigmented areas in 3. The small number of the nevi showing these characteristics did not permit statistical evaluation of their change.

Vascular Structures Vascular structures were observed in 31 nevi monitored in 24 women. The number of dotted vessels, observed in 20 nevi of 18 women, increased significantly at the end of pregnancy (V1 vs. V2, $p<.05$); it had decreased significantly at the postpartum visit (V2 vs. V3,

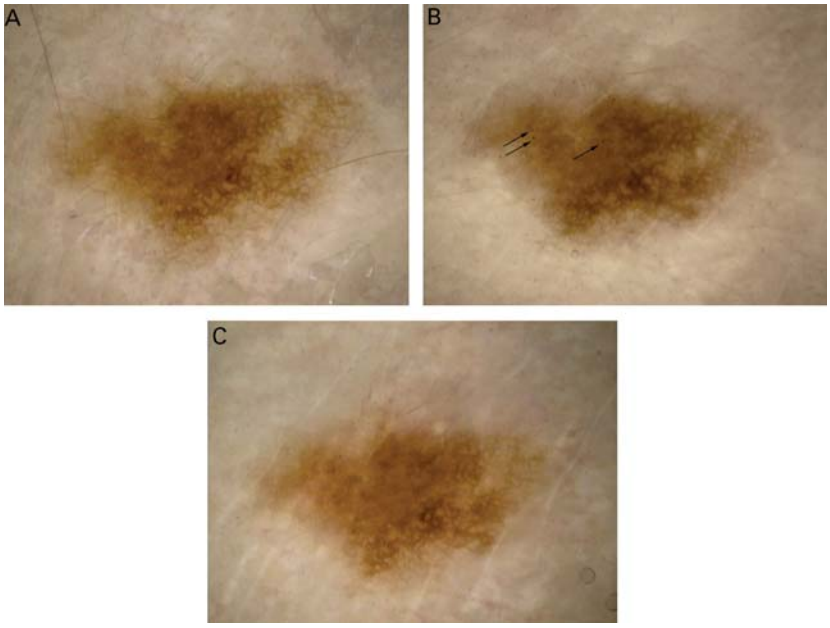

Figure 2. (A) Nevus on sacrogluteal area within the first trimester of pregnancy. (B) At the end of pregnancy an increasing in number and size of dotted vessels is evident in the context of the nevus (black arrows) and, to a lesser extent, in the skin around. (C) Decreased number and size of vessels after delivery.

$p<.05$; Figure 2). Comma-like vessels were present in 18 nevi of 15 women; all observers agreed on their increased presence at the end of pregnancy and this change reached the significance threshold for one observer (observer MRZ, V2 vs. V3, $p<.05$). No statistical differences were observed between the first trimester of pregnancy and the postpartum visit. Arborizing and hairpin vessels were found in only 7 and 4 nevi, respectively. No irregular vessels were observed in the nevi examined.

TDS In the sample, the observers valued differently an increase in TDS at V2 in 11, 17, and 18 nevi, while a successive TDS decrease at the postpartum visit (V3) involved from 18 to 21 nevi. Opposite changes were less commonly observed (Table 2). The mean TDS values, according to the different areas and times, varied from 2.8 to 3.8. In general, higher TDS values were observed at the end of pregnancy, with significant difference between the end of pregnancy and the postpartum visit ($p<.01$), as shown in Figure 3. The mean TDS increased by 2.37% at the end of pregnancy and then significantly decreased by 5.27% at the postpartum visit.

Measures of the Area In the sample examined, the mean values of the areas of the nevi at V1, V2, and V3 were 8.6, 8.9, and 8.7 mm^2, respectively. The mean change in size was $+0.28\,mm^2$ (range, −4.0 to 6.2) between V1 and V2, $-0.16\,mm^2$ (range, −4.2 to 3.9) between V2 and V3, and $+0.12\,mm^2$ (range, −1.8 to 4.3) between V1 and V3. The majority of the nevi increased by less than 1 mm^2 at V2, whereas the most frequent change in the interval between V2 and V3 consisted in a decrease of less than 1 mm^2 (Table 3; Figure 4). These resulting differences, however, were statistically nonsignificant.

TABLE 2. TDS Changes in Our Sample According to The Different Observers*

Period	*TDS variation*†	*Observer MC*	*Observer AV*	*Observer MRZ*	*Mean*
V1→V2	↑	11 (12.8)	17 (19.8)	18 (20.9)	15.3 (17.8)
V1→V2	↓	8 (9.3)	8 (9.3)	6 (7.0)	7.3 (8.5)
V2→V3	↑	4 (4.7)	6 (7.0)	4 (4.7)	4.7 (5.4)
V2→V3	↓	18 (20.9)	21 (24.4)	21 (24.4)	20 (23.3)
V1→V3	↑	6 (7.0)	8 (9.3)	8 (9.3)	7.3 (8.5)
V1→V3	↓	15 (17.4)	14 (16.3)	14 (16.3)	14.3 (16.7)

*Data are reported as number (%). Number and frequency of variations in size of the MN observed. The entity of changes was statistically examined by means of ANOVA-RM.
†↑, increase; ↓, decrease.

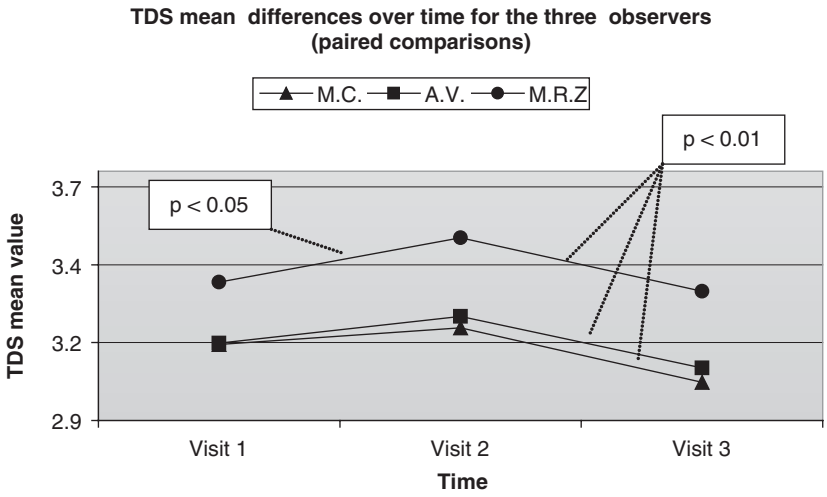

Figure 3. TDS mean differences over time for the three observers. Comparisons were performed paired, i.e., between adjacent visits. Even though one observer (MRZ) presented a higher TDS mean value from the other ones, the differences over time, significant or not, appear to be similar for the three observers. In particular, significant reductions between V2 and V3 are common to all the observers.

Discussion

Subjective clinical changes of pigmented skin lesions have been reported in 10.5%[3] and 32.5%[4] of pregnant women. These changes include pigmented skin lesions located on the breast and abdomen, areas that are subject to physiologic expansion during pregnancy, and nonmelanocytic skin lesions, like skin tags or dermatofibromas. This evidences the scarce reliability of an analysis based on self-examination.

This study investigates the way in which the dermoscopic appearance of acquired MN alters during and after pregnancy. Digital dermoscopic follow-up provides an objective method for the analysis of pigmented skin lesions. To evaluate the intrinsic influence of pregnancy on melanocytic lesions, only nevi located on the back were chosen for the study. Dermoscopic examination of the nevi showed a significant progressive shading of the borders and a clearing of global pigmentation associated with the reduction in number and size of globules; even though not statistically significant, there was also some indication toward the clearing of globules. Both prominence and thickness of network lines and darkness and size of blotches decreased significantly over time. All these resulting changes were particularly significant in the period between the end of pregnancy (V2) and postpartum (V3). It may be hypothesized that most of these dermoscopic changes could be due to the reduced exposure to sunlight reported by almost all the women during the observational period; in fact, it has been documented that, in the case of irradiated MN, most of these parameters show opposite temporarily modifications after exposure to UV light.[10,13]

Dotted vessels and, to a lesser extent, comma-like vessels increased in number at the end of pregnancy (V2) and then they normalized after delivery (V3). These findings may be considered the dermoscopic counterpart of the vascular changes typical of pregnancy, due to both the increase in the blood volume and the proliferation and dilatation of cutaneous blood vessels. Physiologic modifications of vessels are induced by the production of placental hormones, such as estrogens, human chorionic gonadotrophin, adrenocorticotrophic hormone-like substances, luteinizing releasing

TABLE 3. Variation in Size of MN in Our Sample*

	Change (mm^2)				
Period	*≥ + 1*	*0 to + 1*	*0*	*0 to − 1*	*≤ − 1*
V1→V2	15 (17.4)	29 (33.7)	14 (16.3)	23 (26.7)	5 (5.8)
V2→V3	6 (7.0)	19 (22.1)	16 (18.6)	34 (39.5)	11 (12.8)
V1→V3	12 (14.0)	27 (31.4)	15 (17.4)	24 (27.9)	8 (9.3)

*Data are reported as number (%). Number and frequency of variations in size of the MN observed. The entity of changes was examined by means of an ANOVA-RM.

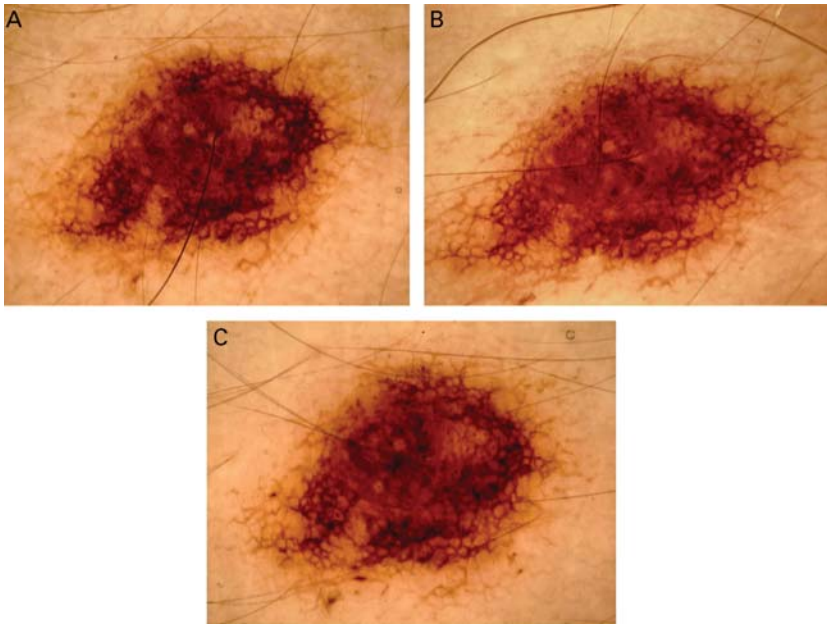

Figure 4. (A) Melanocytic nevus on the lumbar area at the seventh week of pregnancy. Area, 10.8 mm^2. (B) Enlargement of the lesion at the end of pregnancy. Area, 12 mm^2. (C) Decreasing of the size after delivery. Area, 11.1 mm^2.

hormone, and thyrotropin-releasing hormone.[1,14]

The TDS mean value increased by 2.37% at the end of pregnancy and then decreased significantly by 5.27% at the postpartum visit. Our data are in accordance with the observations reported by Gunduz and colleagues[7] who analyzed by means digital dermoscopy 21 MN in a series of 21 pregnant women. The lesions were selected in sites like the back, the face, or the neck, which are poorly influenced by skin expansion related to pregnancy. The images acquired before the 15th week and at the third trimester of pregnancy were evaluated according to the Stolz's ABCD rule, revealing a variation of mean TDS by 3.4 in the first trimester to 3.5 in the third trimester. The increase of the TDS in 4 nevi (19%) at the third trimester was followed by its decline 6 months after delivery.

In our study, symmetry of both the colors and the dermoscopic structures appeared more pronounced at the postpartum visit than in the first or third trimester of pregnancy, suggesting a more regular appearance of the nevi after pregnancy. Gunduz and colleagues and our findings suggest that the increase in the TDS and changes in symmetry during pregnancy may reflect some degree of hormonal influence on melanocytic activity, leading temporarily to a slightly more irregular dermoscopic aspect. These dermoscopic features may be related to the low degree of histologic atypia and activation described by Foucar and coworkers.[4] An increased number of estrogen and progesterone receptors has been demonstrated in MN of pregnant women and has been related to the pigmentary changes observed in pregnancy.[15] In the case described by Lee and colleagues,[16] however, a melanocytic nevus showed a marked enlargement during pregnancy followed by postpartum regression, but estrogen and progesterone receptors were not found in the biopsy specimen during gestation, nor after delivery.

A further study reported the dermoscopic features of nevi in 12 pregnant women examined in the second and third trimesters of pregnancy.[8] In the areas influenced by the stretching typical of pregnancy, like the abdomen and the breast, pigmented lesions with a reticular pattern showed enlargement without change in shape, whereas lesions with a globular pattern also presented a peripheral increase in the number of globules. These findings were explained as a consequence of the stretching of the skin, which brings deep nests of melanocytes to a more superficial location simulating junctional nests. Nevi located in other areas, which are scarcely modified by the physiologic morphologic changes of pregnancy, like the back, did not vary significantly in shape and in color.

We found a temporary development, however, of a peripheral rim of globules in two nevi

located on the back, in the scapular and in the lumbar areas, respectively. These changes almost completely regressed 6 months after delivery.

In this study, the most frequent changes in the size of the nevi were an increase during pregnancy (51.2%) and a decrease in the postpartum period (52.3%); however, the entity of these changes was generally small and the size did not appear to modify significantly over time. Perhaps a mild edema due to the increased blood flow could induce minimal and transient skin extension during pregnancy. The frequency of the changes in size was different from that reported in photographic follow-up of Pennoyer and coworkers,[5] which only studied nevi located on the back to minimize the effect of the pregnancy-related stretching of the skin. Among the 129 nevi monitored at the first and third trimesters of pregnancy, 8 (6.2%) were seen to change in size: 4 increased by 1 mm and 4 decreased by 1 mm at the end of pregnancy. The different frequency of changes may be due to the higher sensitivity of our computer-assisted measurement system, compared with the standard millimeter ruler, used by Pennoyer and coworkers.[5] As in our study, however, the changes in size were not considered significant.

In conclusion, digital dermoscopy confirms its importance in the identification of structural variations of nevi over time. The most important dermoscopic changes in MN during and after pregnancy were shown to be the development of vascular structures, mainly dotted and comma-like, and the increase in the TDS value at the third trimester of pregnancy. This was probably due to hormonal influence on melanocytic activity. Generally, these modifications were temporary, as the nevi returned to their prior appearance in most cases. Although nevi are commonly said to enlarge during pregnancy, enlargement appears to be strongly related to the anatomic area, as the intrinsic hormonal activity does not seem to significantly affect the size of the nevi.

Acknowledgment The authors thank Giuseppe Gilli (Electronic Data Processing Programmer, Health Physics Department, St Anna University Hospital, Ferrara) for his precious contribution to the statistical analysis.

References

1. Elling SV, Powell FC. Physiological changes in the skin during pregnancy. Clin Dermatol 1997;15:35–43.
2. Kroumpouzos G, Cohen LM. Dermatoses of pregnancy. J Am Acad Dermatol 2001;45:1–19.
3. Sanchez JL, Figueroa LD, Rodriguez E. Behavior of melanocytic nevi during pregnancy. Am J Dermatopathol 1984;6:89S–91S.
4. Foucar E, Bentley TJ, Laube DW, Rosai J. A histopathologic evaluation of nevocellular nevi in pregnancy. Arch Dermatol 1985;121:350–4.
5. Pennoyer JW, Grin CM, Driscoll MS, et al. Changes in size of melanocytic nevi during pregnancy. J Am Acad Dermatol 1997;36:378–82.
6. Ellis DL Pregnancy and sex steroid hormone effects on nevi of patients with the dysplastic nevus syndrome. J Am Acad Dermatol 1991;25:467–82.
7. Gunduz K, Koltan S, Sahin MT, Filiz E. Analysis of melanocytic naevi by dermoscopy during pregnancy. J Eur Acad Dermatol Venereol 2003;17:349–51.
8. Strumia R. Digital epiluminescence microscopy in nevi during pregnancy. Dermatology 2002;205:186–7.
9. Argenziano G, Soyer HP. Dermoscopy of pigmented skin lesions. a valuable tool for early diagnosis of melanoma. Lancet Oncol 2001;2:443–9.
10. Hofmann-Wellenhof R, Soyer HP, Wolf IH, et al. Ultraviolet radiation of melanocytic nevi: a dermoscopic study. Arch Dermatol 1998;134:845–50.
11. Hofmann-Wellenhof R, Wolf P, Smolle J, et al. Influence of UVB therapy on dermoscopic features of acquired melanocytic nevi. J Am Acad Dermatol 1997;37:559–63.
12. Stolz W, Riemann A, Cognetta AB. ABCD rule of dermoscopy: a new practical method for early recognition of malignant melanoma. Eur J Dermatol 1994;4:521–7.
13. Stanganelli I, Bauer P, Bucchi L, et al. Critical effects of intense sun exposure on the expression of epiluminescence microscopy features of acquired melanocytic nevi. Arch Dermatol 1997;133:979–82.
14. Barankin B, Silver SG, Carruthers A. The skin in pregnancy. J Cutan Med Surg 2002;6:236–40.
15. Ellis DL, Wheeland RG. Increased nevus estrogen and progesterone ligand binding related to oral contraceptives or pregnancy. J Am Acad Dermatol 1986;14:25–31.
16. Lee HJ, Ha SJ, Lee SJ, Kim JW. Melanocytic nevus with pregnancy-related changes in size accompanied by apoptosis of nevus cells: a case report. J Am Acad Dermatol 2000;42:936–8.

Address correspondence and reprint request to: Annarosa Virgili, MD, Department of Clinical and Experimental Medicine, Section of Dermatology, University of Ferrara, Via Savonarola 9, 44100 Ferrara, Italy, or e-mail: vri@unife.it.